



UWI

ST. AUGUSTINE CAMPUS
TRINIDAD & TOBAGO, WEST INDIES

An Audit; Evaluation of patient positioning and preparation errors on panoramic radiographs at The University of The West Indies Dental School, Trinidad

SA. Pegus, A. K. Bissoon, R. Hunte

Email: scottpegus10@gmail.com, arlana.bissoon@sta.uwi.edu

ABSTRACT

Objective: To evaluate the frequency of common operator errors seen on panoramic radiographs in the UWI Dental School in Trinidad and Tobago.

Design and Methods: Previously published and established error categories were used to assess 400 panoramic radiographs. Each positioning error and its resultant identifying features on the panoramic radiographs were assessed. Microsoft Office Excel 2007 was used as the primary tool to record the presence or absence of each error on the radiograph.

Results: 400 panoramic radiographs were analyzed at the University of the West Indies, School of Dentistry. Out of the 400 panoramic radiographs, 40.5% showed no preparation or positioning errors according to the 8 criteria. The most common error observed was where the patient's chin was tipped too low (21%), followed by rotation of the head (12.50%). The least frequent error observed was where the patient's head was positioned too far forward (0.50%).

Conclusions: The high frequency of errors revealed in this research project highlight the need for additional training in panoramic radiography technique to increase the diagnostic yield of this imaging modality at the institution. However compared to the last audit conducted in Trinidad and Tobago, there has been a reduction in the number of radiographs showing multiple errors which can be attributed to increased awareness and training of operators since its publication.

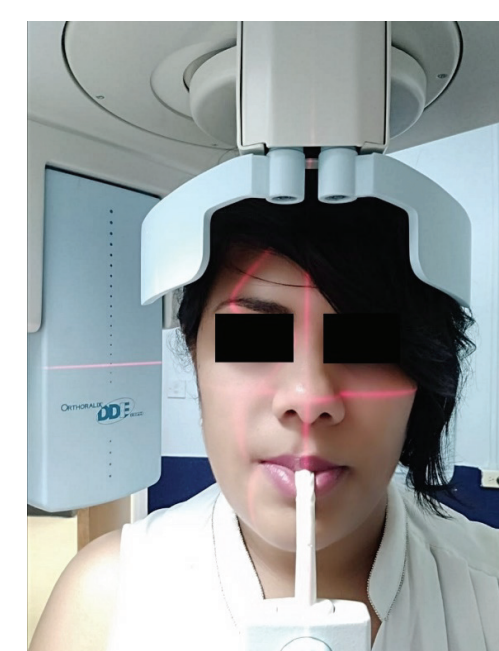
INTRODUCTION

Dental panoramic radiography is a technique used to produce images of jaws, their respective dentitions, and supporting structures on a single image. Panoramic radiography is a difficult radiographic technique to perfect and panoramic radiographs are known to be difficult to expose without errors¹. In order to minimize errors in dental panoramic tomography, it is important to position the patient in the focal trough precisely according to the manufacturer's specification². The preparation of the patient and positioning of the patient's head within panoramic equipment is crucial to the diagnostic quality of the image. Common technical errors and artifacts can lead to inadequate diagnostic quality of images^{3,4}.

The aim of this study was to evaluate the frequency of common operator errors seen on panoramic radiographs in the UWI Dental School in Trinidad and Tobago.

METHODS

Approval was granted by the University of the West Indies Campus Research Ethics Committee. Subjects included patients in permanent dentition attending the UWI Dental School Clinics. Edentulous patients were excluded. A total of 400 panoramic radiographs were assessed. These panoramic radiographs generated by Gendex Orthoralix 9200 DDE© were reviewed digitally in a darkened room. Previously published and established error categories⁵ were used to assess each radiograph. To evaluate reliability for assessing patient preparation and positioning errors, an Oral and Maxillofacial Radiologist was included to independently assess 50 radiographs from the sample. The same 50 radiographs were then assessed utilizing the same parameters by the principal investigator and the errors identified were compared. Microsoft Office Excel 2007 was used to record the presence or absence of each error on the radiograph and analyse the data.



Picture showing patient positioned in panoramic machine with three light markers which guide accurate head position.

RESULTS

Both examiners, were in agreement with the identification of both preparation and positioning errors in 48 out of 50 radiographs analyzed. Out of the 400 panoramic radiographs, 40.5% showed no preparation or positioning errors according to the 8 criteria. The most common error observed was where the patient's chin was tipped too low (21%), followed by rotation of the head (12.50%). The least frequent error observed was where the patient's head was positioned too far forward (0.50%).

Figure 1: Comparison of frequency distribution of positioning errors on panoramic radiographs at UWI Dental School

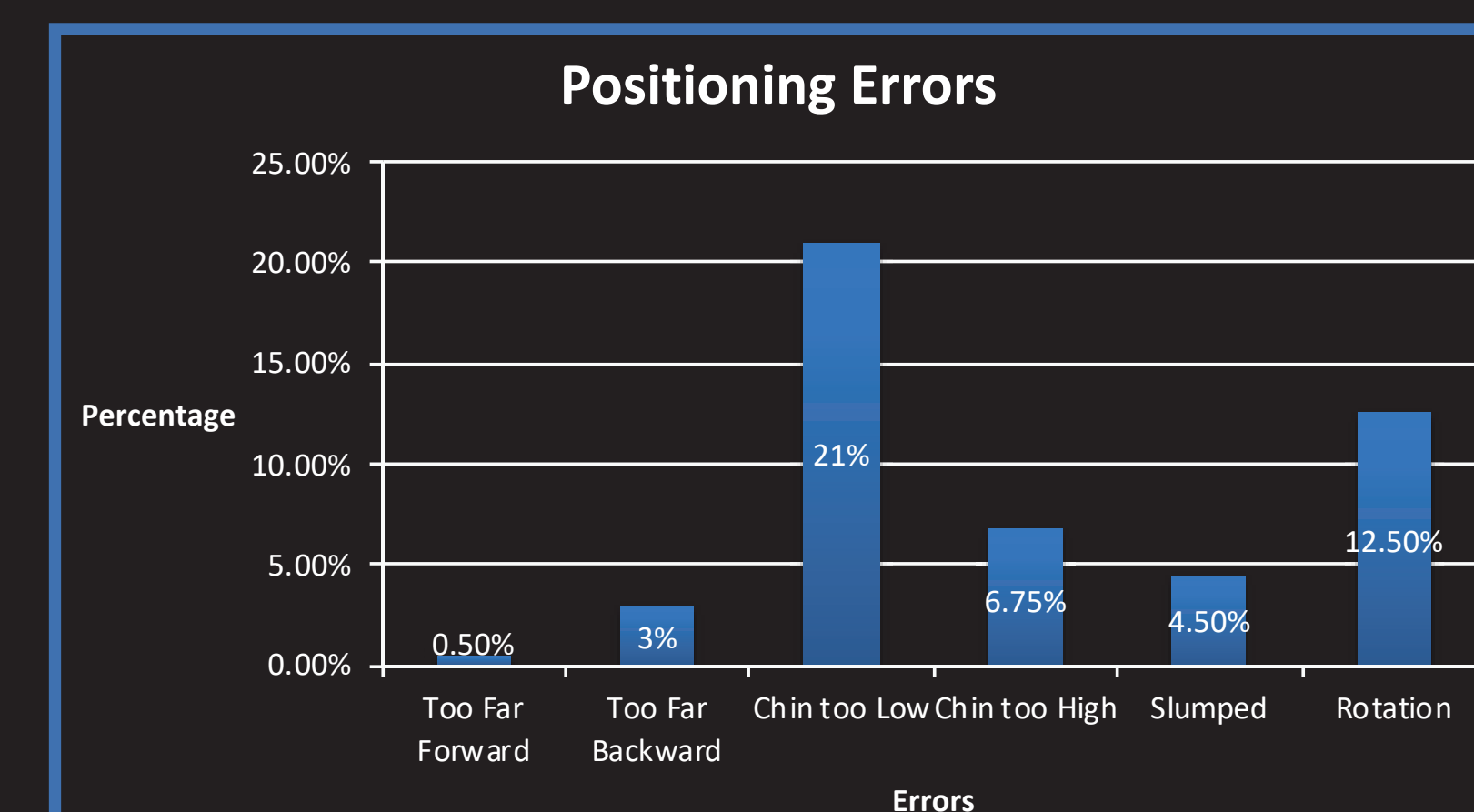
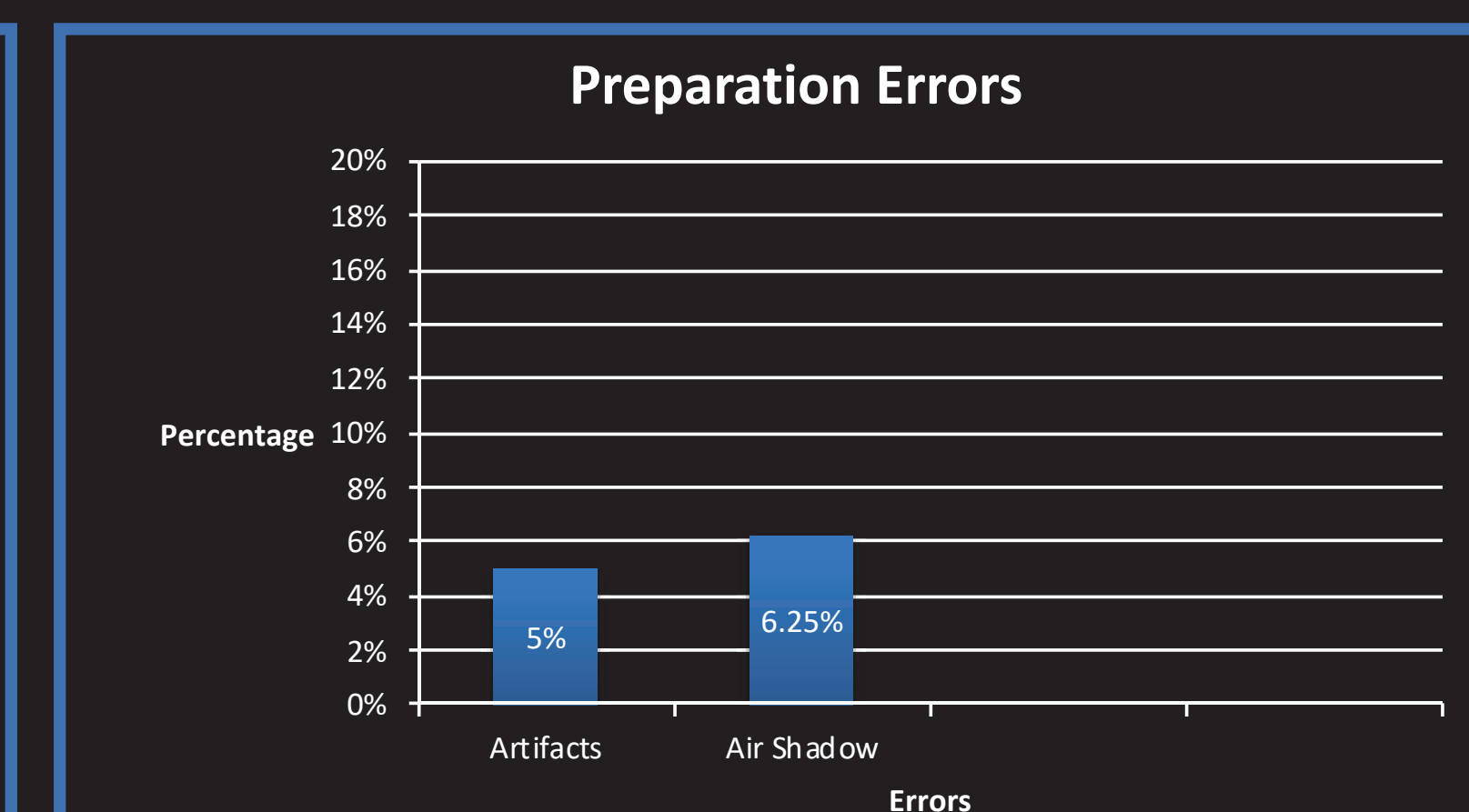


Figure 2: Comparison of frequency distribution of preparation errors on panoramic radiographs at UWI Dental School



Examples of errors on panoramic radiographs analyzed at the UWI School of Dentistry

Figure 3: Chin tipped too low resulting in excessive curving of the occlusal plane and loss of image of the roots on the lower anterior

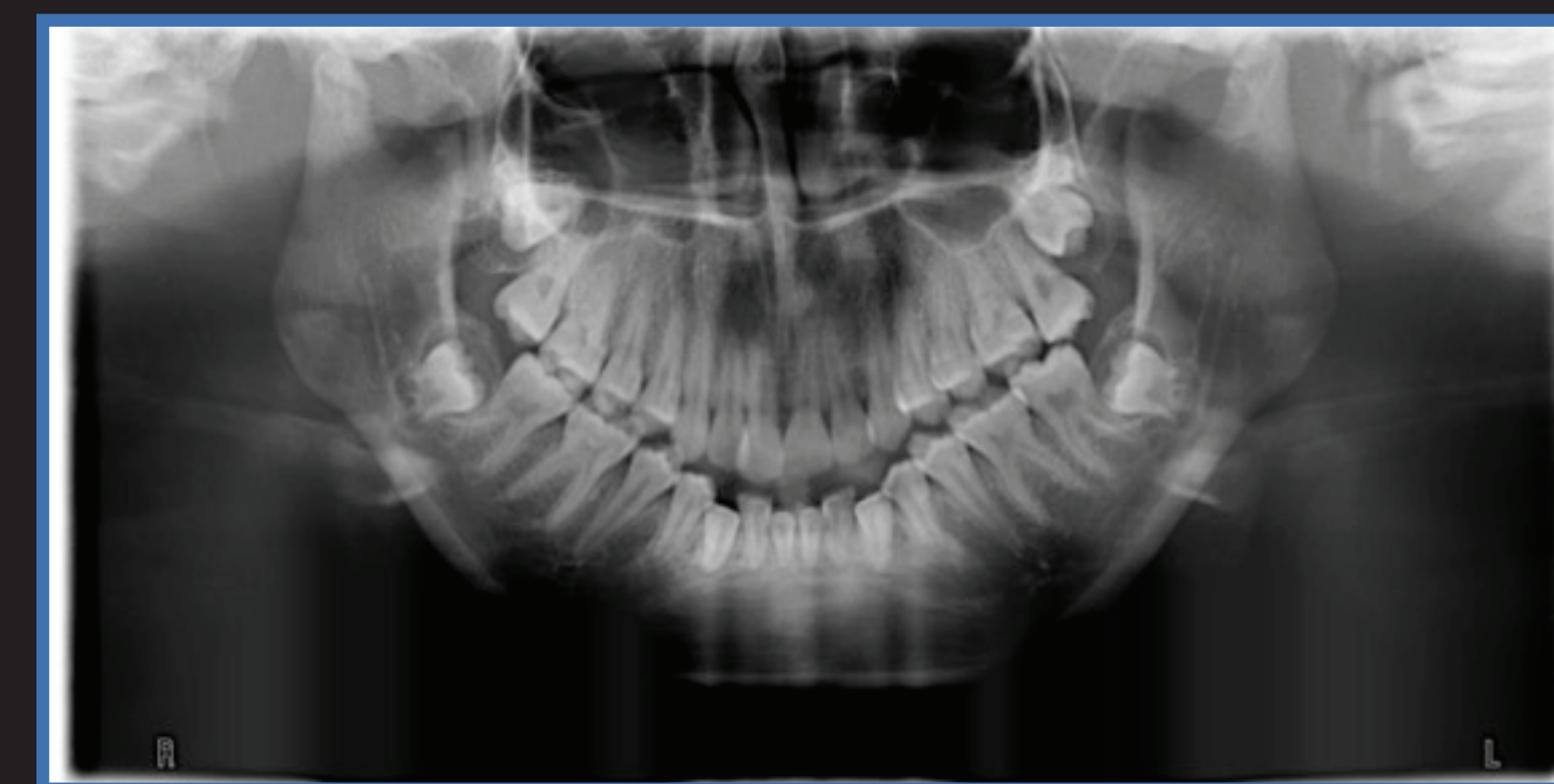

Figure 4: Patient rotated to the right - unequal right to left magnification of posterior teeth and rami (horizontal positioning error)

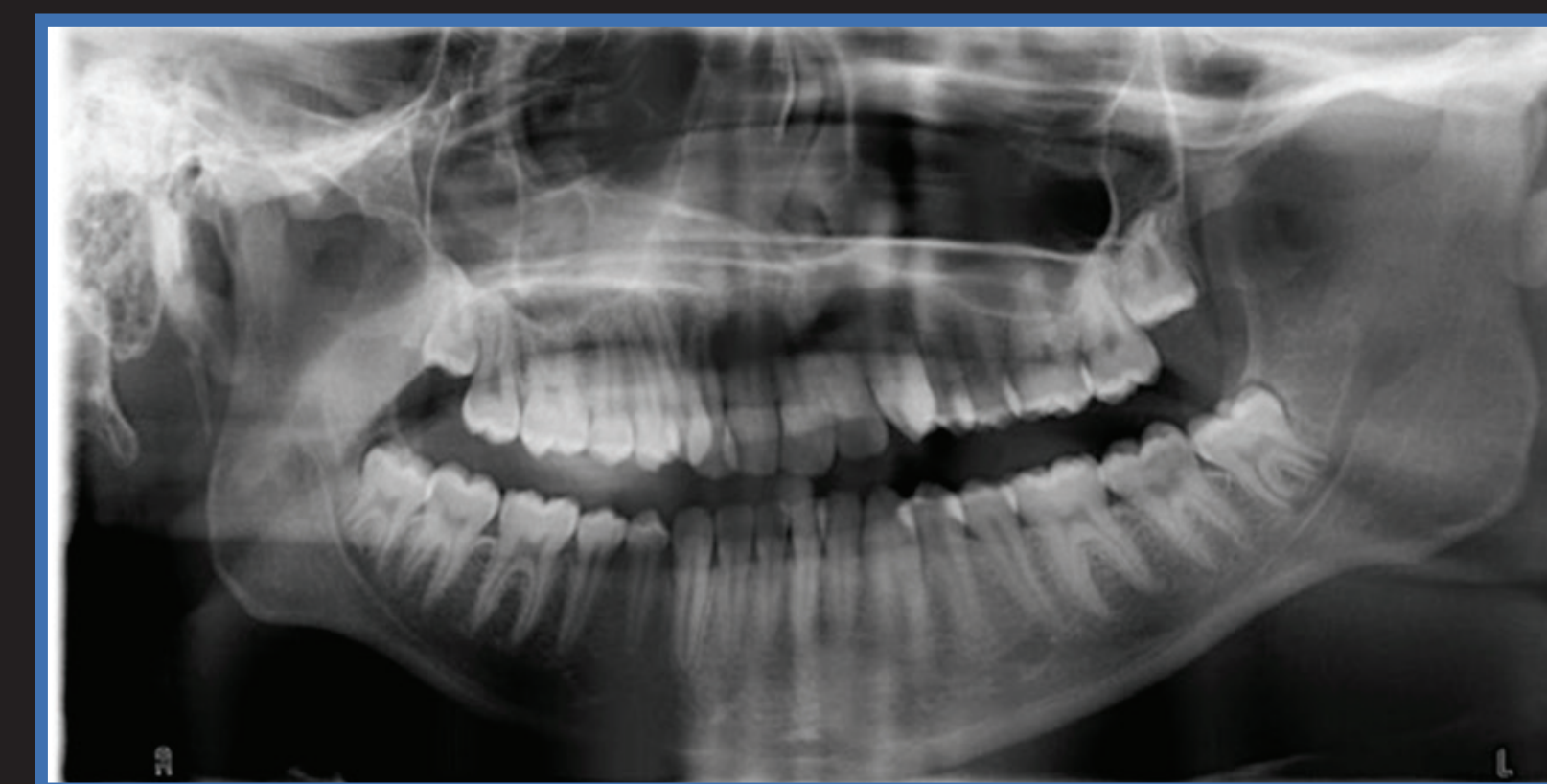


Figure 5: Failure to place the tongue on the palate during the exposure resulting in superimposition of palatoglossal air shadow on maxillary apices

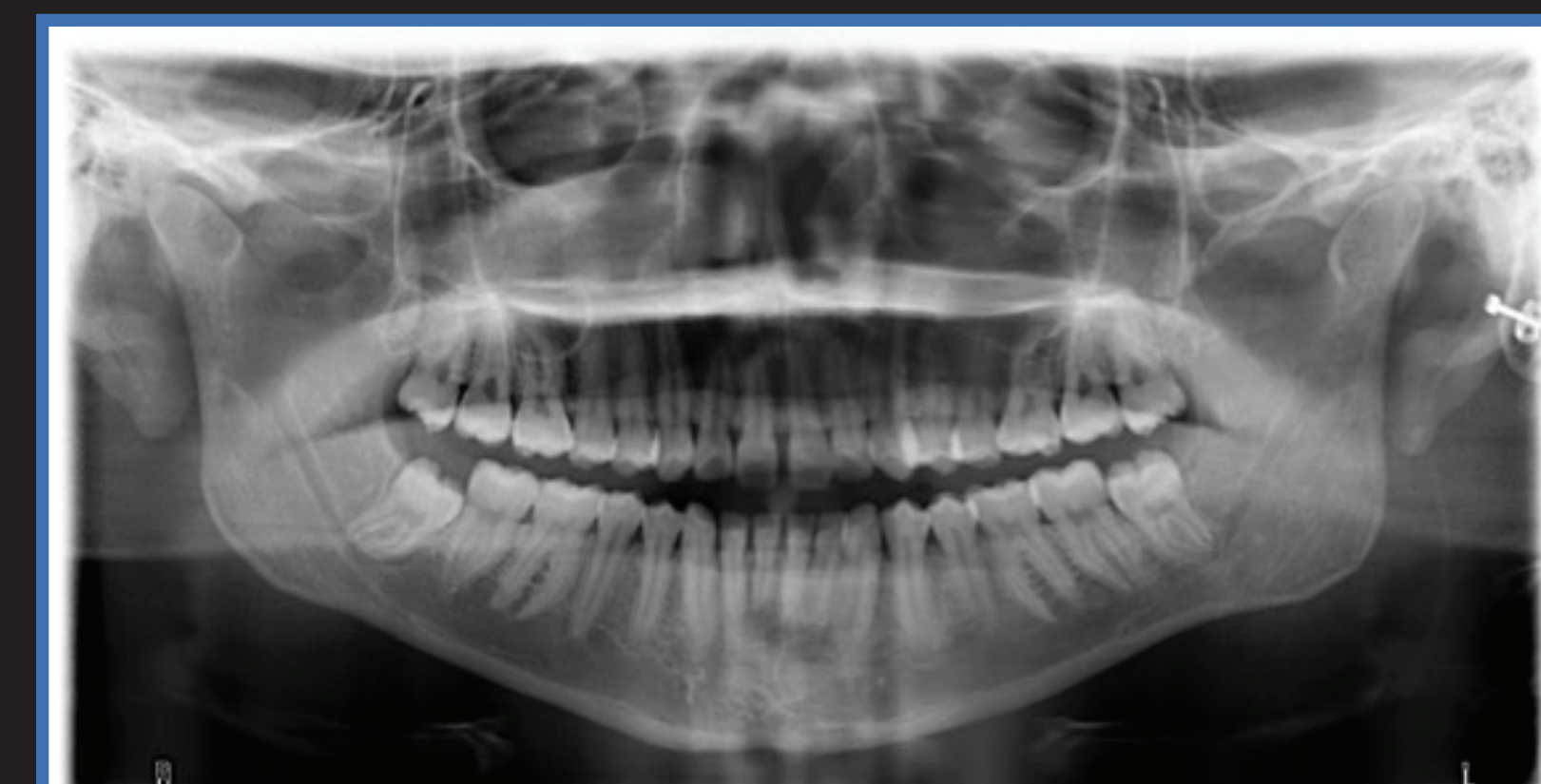
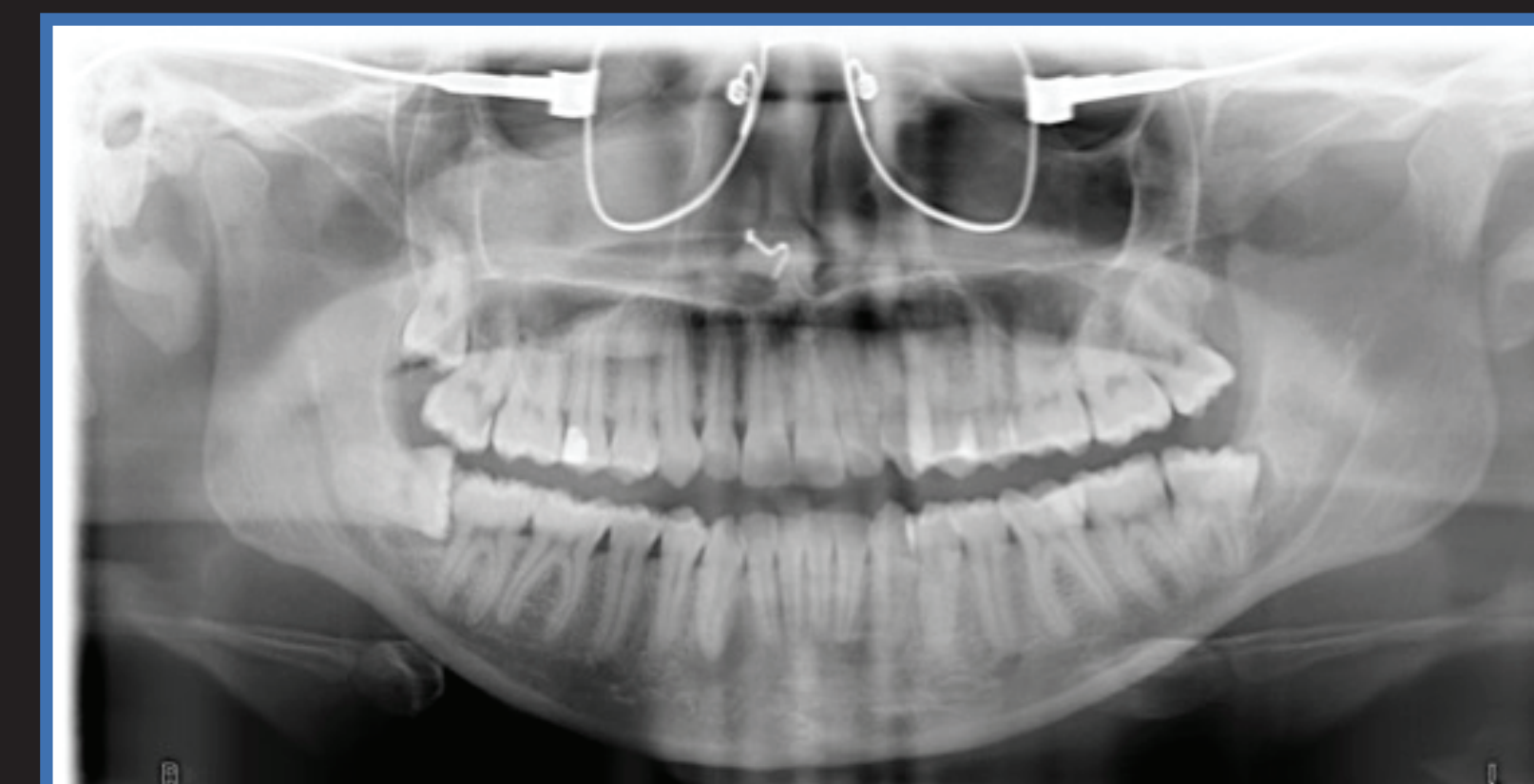


Figure 6: Failure to remove spectacles and nose ring resulting in radiopaque artifacts



DISCUSSION

Panoramic Radiographs are important diagnostic tools related to diagnosis of dental conditions. It is important to take optimal quality panoramic radiographs since poor quality radiographs result in the need to retake images, which has several negative consequences. The most serious of which are the additional radiation dose to the patient. Given the 2007 recommendations of the International Commission on Radiological Protection which resulted in an upward reassessment of fatal cancer risk from oral and maxillofacial radiographic examinations, it is important that retakes are kept at a minimum⁶. There is also an increase in cost associated with retake of radiographs and extended dental examination times. This increase in cost affects both the patient and the dental school. The results showed more than half (59.5%) of the panoramic radiographs taken at the UWI School of Dentistry by dental interns who underwent additional training in panoramic radiography contained one or more positioning errors. This is consistent with other studies Dhillon et al⁷, Subbulakshmi AC et al⁸. In a previous study carried out by Bissoon et al⁹ of panoramic radiography errors generated by radiographers in Trinidad and Tobago, 94.2% of the panoramic radiographs contained one or more positioning errors. This research project revealed a great reduction (34.7%) in the amount of radiographs showing errors in the same country. The finding of a reduction in the number of radiographs with errors may be attributed to increased formal training done at the dental school with dentists following their graduation from the undergraduate program. In this study, different categories of panoramic radiography errors were analyzed. Processing errors, which also affect the diagnostic yield, were not included since radiographs were taken from a digital panoramic machine. It was observed that the highest frequencies of errors were due to the patient positioning particularly the chin being placed too low in the focal trough. (21%). This error leads to excessive curvature of the occlusal plane, loss of image of the roots of anterior teeth and narrowing of the intercondylar distance and loss of the heads of the condyles at the edges of the image⁵.

The second most common error noted was the rotation of the head (12.50%). Careful attention must be paid to the position of the light beam marker for the mid-sagittal plane before the exposure is carried out. This finding is in agreement with a previous study on evaluation of panoramic radiograph errors by Kaviani et al¹⁰. Rotation of the head leads to discrepancies in horizontal magnification of integral structures and interferes with diagnostic interpretation. In terms of other positioning errors, multiple errors occurred in one image; this could be due to spending inadequate time for patient preparation and positioning.

One limitation of this study included that the radiographs were generated by multiple operators at the Dental School which could lead to differences in error frequencies. Additionally, the principal investigator possessed an undergraduate degree in dentistry and no postgraduate qualifications in Oral and Maxillofacial Radiology.

CONCLUSION

The high frequency of errors revealed in this research project highlight the need for additional training in panoramic radiography technique to increase the diagnostic yield of this imaging modality at the institution. However compared to the last audit conducted in Trinidad and Tobago, there has been a reduction in the number of radiographs showing multiple errors which can be attributed to increased awareness and training of operators since its publication.

REFERENCES

- Kullman L, Joseph B. Quality of digital panoramic radiography in a newly established dental school. *Swed Dent J* 2006;30(4):165-70
- Yeo DK, Freer TJ, Brockhurst PJ Distortions in panoramic radiographs. *Aust Orthod J*. 2002 Nov;18(2):92-8.
- Rumberg H, Hollender L, Oda D. Assessing the quality of radiographs accompanying biopsy specimens. *J Am Dent Assoc*. 1996 Mar; 127(3):363-8.
- Brown RS, Coleman-Bennett MM, Jones-Matthews T. Synthetic hair braid extension artifacts in panoramic radiographs. *J Am Dent Assoc*. 1998 May; 129(5):601-4.
- Langland O, Langlais R, Prece J. Principles of Dental Imaging. USA: Lippincott Williams & Wilkins 2002.
- Ludlow JB, Davies-Ludlow LE, White SC. Patient risk related to common dental radiographic examinations. *J Am Dent Assoc* 2008; 139:1237-1243
- Manu Dhillon, Srinivasa M Raju, Sankalp Verma, Divya Tomar. Positioning errors and quality assessment in panoramic radiography. *Imaging Sci Dent*. 2012 Dec; 42(4): 207-212
- Subbulakshmi A C, Mohan N, Thiruneervannan R, Naveen S, Gokulraj S. Positioning errors in digital panoramic radiographs: A study. *J Orofac Sci* 2016; 8:22-6
- Bissoon AK, Whaites E, Moze K, Naidu R. Evaluation of common operator errors in panoramic radiography in Trinidad and Tobago: a comparison of formally vs informally trained operators. *West Indian Med J*. 2012 Oct; 61(7): 733-8.
- Kaviani F, Johari M, Esmaili F. Evaluation of Common errors of Panoramic errors in Tabriz Faculty of Dentistry. *JODDD*. 2008; Vol. 2, No. 3