

## Missile Injury by A Weed Wacker Resulting in a False Aneurysm of the Brachial Artery

Vijay Naraynsingh and Michael J. Ramdass\*

Department of Clinical Surgical Sciences, University of the West Indies, St. Augustine, Trinidad & Tobago, West Indies

**Abstract:** A novel now commonly used device in many countries called a “weed-wacker” is a mechanical rotating device with a cord used to trim lawns and grass. A case of a 14-year old boy with a false aneurysm of the brachial artery is presented; he sustained a missile injury by a piece of rusty steel projected by use of a weed wacker. Missile injuries by nail guns and bullets have been documented in the literature; however, this mechanism of injury by a weed-wacker has never been previously described and is presented as a unique mechanism of injury and brings attention the issue of safety with the use of the weed-wacker.

**Keywords:** False aneurysm, pseudoaneurysm, brachial artery, weed wacker, accidental injury.

### BACKGROUND

Many mechanisms of vascular penetrating trauma have been published affecting almost any artery in the human anatomy the most common being false aneurysm formation as a result of stab or gunshot injuries. We have encountered a most unusual form of penetrating trauma involving a “weed wacker” and wish to add this to the literature to increase awareness for emergency physicians and surgeons.

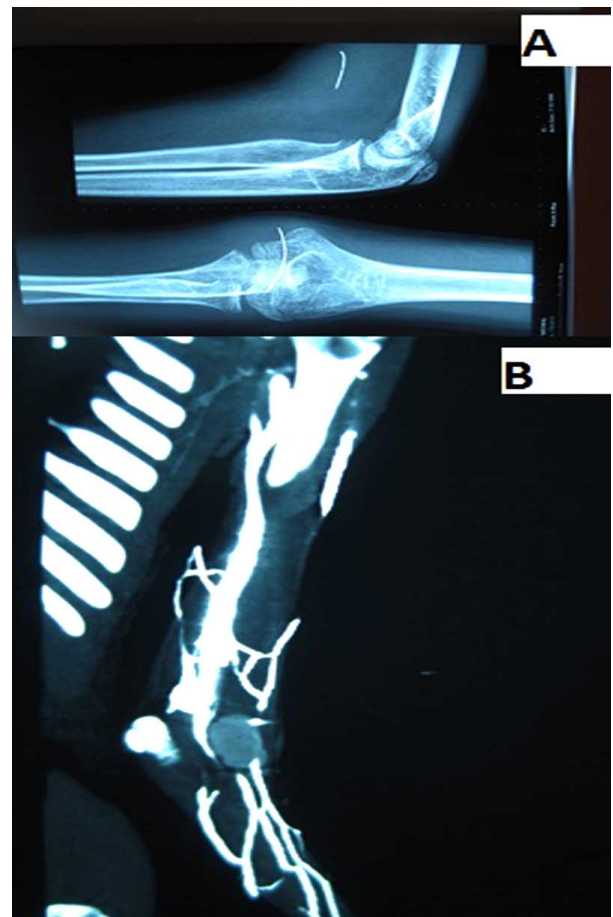
### CASE PRESENTATION

A 14-year old boy was standing approximately 15 feet away from his father who was using a weed-wacker to trim his lawn at home. The boy suddenly felt something hit him in the left antecubital fossa, noticed no bruising or bleeding and thought nothing of it.

After a 2-week period he observed a swelling in the antecubital fossa which was tender and erythematous. He was referred to the paediatric orthopaedic unit on duty where a diagnosis of cellulitis was made and a week of outpatient oral antibiotic treatment was administered. The swelling and pain increased and he returned to Hospital, where a plain radiograph and CT angiogram revealed a metallic foreign body lodged in the antecubital fossa Fig. (1A,B), resulting in a false aneurysm of the brachial artery and absent radial pulse.

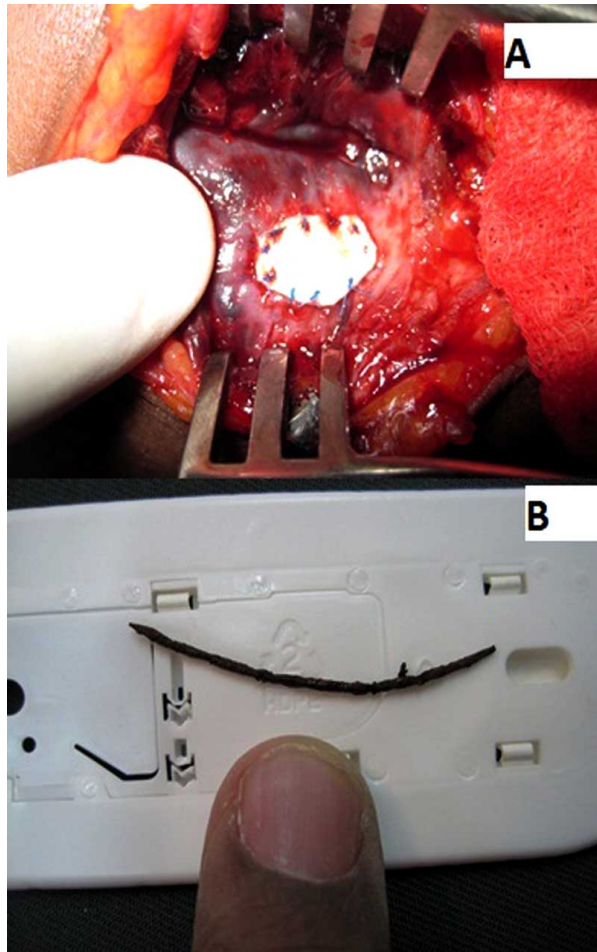
At exploration of the brachial artery an infected false aneurysm was confirmed with a 2mm defect in the vessel wall and the foreign body (a length of rusty metal wire) removed. The infected clot was removed and the defect patched with Gore-Tex® (ePTFE) and sutured with 6.0 prolene Fig. (2A,B). The patient was kept on intravenous

antibiotics for 5 days and discharged. He had an uneventful recovery with excellent pulses at the wrist.



**Fig. (1A).** Radiograph showing metallic foreign body lodged in the brachial artery and, **(B)** CT angiogram showing brachial artery false aneurysm.

\*Address correspondence to this author at the University of the West Indies, Department of Surgery, General Hospital, Port-of-Spain, Trinidad, West Indies; Tel: (868) 731 1535; Fax: (868) 221 8068; E-mail: jimmyramdass@gmail.com



**Fig. (2A).** Exploration of brachial artery with GoreTex patch and, **(B)** Metallic foreign body removed from brachial artery.

## DISCUSSION

A weed-wacker is a novel rotatory mechanical device used quite commonly worldwide for cutting grass and keeping lawns well manicured. This is an unfortunate case of penetrating missile injury from use of a weedwacker, whereby a bystander was hit with a piece of steel wire projected to the antecubital fossa. Interestingly, the patient did not realize that a foreign object had entered since it occurred so quickly, inadvertently and with such high velocity. Additionally, the Orthopaedic team seeing patient assumed this to be a simple case of cellulitis before radiographs and ultrasound investigations were requested.

In a literature search on PubMed there are many reported cases of missile embolism from gunshot wounds affecting almost every part of the body with embolisation [1, 2].

There is one case reported with a nail-gun injury to the posterior cerebral artery *via* the roof of the mouth [3] and only one report on an ophthalmology website reporting a

“weed wacker injury” to the cornea *via* a similar mechanism as the case in this report [4].

Two points are made in this article. The first notes the potential danger of use of a weedwacker and its possibility to induce high velocity missile injuries. The second emphasizes safety of use of PTFE in potentially infected fields such as a false aneurysm. The literature endorses this view from several articles published on the topic showing that PTFE maintains its structural integrity in the presence of well-entrenched infection, with a relatively small incidence of anastomotic disruption related to host artery necrosis [5-7].

## CONCLUSION

We recommend that in any injury occurring near the site of a working weed-wacker a penetrating missile injury should be considered even if the trauma appears trivial. Appropriate investigations and treatment should be instituted for these cases. Additionally, the issue of safety with use of protective gear and a shield for the weed-wacker is brought to the forefront for this commonly used tool.

## COMPETING INTERESTS

The authors declare that they have no competing interests.

## CONFLICT OF INTEREST

None declared.

## ACKNOWLEDGEMENTS

None declared.

## REFERENCES

- [1] Ntlhe LM, Komati SM, Fourie PA, Rossouw AP. Missile embolism--pulmonary vein to systemic bullet embolism: a case report and review of the literature. *S Afr J Surg* 2008; 46(2): 58-60.
- [2] Meeks T, Nwomeh B, Abdessalam S, Groner J. Paradoxical missile embolus to the right superficial femoral artery following gunshot wound to the liver: a case report. *J Trauma* 2004; 57(6):1338-40.
- [3] Rezai AR, Lee M, Kite C, Smyth D, Jafar JJ. Traumatic posterior cerebral artery aneurysm secondary to an intracranial nail: case report. *Surg Neurol* 1994; 42(4): 312-5.
- [4] Sun Y. Case Report: Weedwacker Spoke Embedded in the Cornea. *Ophthalmology Web* [Google Search, Cited 2011 Feb 26]. (<http://www.ophtalmologyweb.com/FeaturedArticle.aspx?spid=105&aid=417>).
- [5] Stone KS, Walshaw R, Sugiyama GT, Dean RE, Dunstan RW. Polytetrafluoroethylene versus autogenous vein grafts for vascular reconstruction in contaminated wounds. *Am J Surg* 1984; 147(5): 692-5.
- [6] Shah PM, Ito K, Clauss RH, Babu SC, Reynolds BM, Stahl WM. Expanded microporous polytetrafluoroethylene (PTFE) grafts in contaminated wounds: experimental and clinical study. *J Trauma* 1983; 23(12): 1030-3.
- [7] White WA, Smego DR, Barone JE. Arterial substitution in lower extremity trauma: autogenous vein vs polytetrafluoroethylene. *Conn Med* 1992; 56(10): 525-8.